SonoPath
Clinical Sonography & Telecytology
EDUCATIONAL TELECONSULTATION SERVICES™

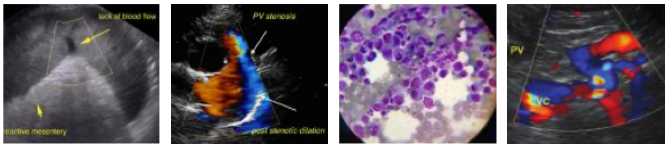

SonoPath.com
1-800-838-4268 info@sonopath.com

PATIENT
Kobe Negron Torres

SPECIES
Canine

BREED
Siberian Husky Mix

SEX
Intact Male

AGE
5 years

WEIGHT
53 lbs

INTERPRETED BY
Andrea Nicastro, DVM, Diplomate ACVIM (*Small Animal Internal Medicine*)

IMAGING PERFORMED BY
Dr. Ferrer, DVM

HOSPITAL NAME
Paseos VC 12474

REFERRING VET
Dra. Enid Mendoza Rosado

INVOICE

DATE
3.22.23

PRESENTING CLINICAL SIGNS

History: The patient presented as a referral for an abdominal ultrasound to evaluate for possible cryptorchism. The patient was present for an annual medical evaluation and bilateral cryptorchidism was noticed. Testosterone levels performed on 1/27/23 resulted intact. Exploratory surgery was explained to the owner since not know the exact location of the testicle. Also recommended ultrasound abdominal before any other procedure.

Abnormal PE/Chem/CBC/UA Results:
PE: no testicles present in the scrotum CBC: WNL CHEM: WNL TESTOSTERONE: 2.8

ULTRASONOGRAPHIC EXAMINATION OF THE ABDOMEN

Urinary System

The urinary bladder wall is normal in thickness and the mucosal surface is smooth. The bladder is moderately distended. Luminal contents are anechoic. No cystic calculi are observed. The region of the trigone and visible portion of the proximal urethra are normal.

The prostate is enlarged (3.22 cm in width) with smooth peripheral contours. Parenchyma is hyperechoic relative to surrounding omental fat and slightly heterogenous in appearance. No distinct focal lesions are observed. The prostatic urethra is not overtly dilated.

The left kidney is normal in size (7.13 cm in length) with a normal shape, architecture and smooth peripheral margins. There is a normal 1:3 cortex to medulla ratio with normal corticomedullary distinction. There is no evidence of pyelectasia, nephroliths, infarcts or hydroureter.

The right kidney is normal in size (7.31 cm in length) with a normal shape, architecture and smooth peripheral margins. There is a normal 1:3 cortex to medulla ratio with normal corticomedullary distinction. There is no evidence of pyelectasia, nephroliths, infarcts or hydroureter.

Adrenal Glands

The left adrenal gland is normal in size (0.46 cm at cranial pole) (0.43 cm at caudal pole) (2.42 cm in length) with a normal shape and homogenous parenchyma. The glandular echogenicity and detail are unremarkable. Capsule, cortex, and medullary definition are normal. The phrenicoabdominal vein and surrounding vasculature are normal.

The right adrenal gland is in normal size (1.14 cm at cranial pole) (0.52 cm at caudal pole) with a normal shape and homogenous parenchyma. The glandular echogenicity and detail are unremarkable. Capsule, cortex, and medullary definition are normal. The phrenicoabdominal vein and surrounding vasculature are normal.

Spleen

The spleen is normal in size (1.41 cm in width at the level of the hilus) with a normal capsular contour. There is appropriate echogenicity and echotexture. No focal lesions are observed. Splenic vasculature is normal.

Liver

The liver is subjectively normal in size with normal contours and structure. There is appropriate echogenicity and echotexture. No overt structural evidence of inflammatory, infiltrative, or regenerative pathology is evident. Vascular and biliary tracts are of normal volume with no evidence of congestion. No pathological hepatic lymphadenopathy observed.

The gall bladder lumen is moderately distended. The wall is thin and smooth. A moderate amount of

mostly gravity-dependent echogenic debris/sludge is observed within the lumen. The cystic and common bile ducts are normal/not seen.

Gastrointestinal
The lumen is not distended. The gastric wall is normal in thickness with a normal layering pattern. The small intestinal lumen is not dilated. The small intestinal wall thickness is normal with a normal layering pattern and appropriate mural detail. Discreet masses are not identified. The ileocecocolic junction and colonic wall are normal. There is no evidence of an obstructive pattern.

Pancreas
The region of the pancreas is isoechoic relative to surrounding omental fat. No obvious parenchymal abnormalities are observed. There is no evidence of regional inflammation or effusion.

Free Abdomen
The peritoneal cavity is normal. There is no evidence of inflammation or effusion. One prominent mesenteric lymph node is visualized (measuring 1.01 cm in length). It is normal in shape and echogenicity.

Other
Both testicles appear to be within the abdominal cavity (left: 2.09 x 1.32 cm) (right: 1.96 x 1.86 cm). The right testicle is at the level of the urinary bladder neck. The location of the left testicle within the abdominal cavity difficult to determine based on the available images.

ULTRASONOGRAPHIC FINDINGS

- Bilaterally cryptorchid testicles
- The prostate changes are most consistent with benign prostatic hyperplasia.

INTERPRETATION OF THE FINDINGS & FURTHER RECOMMENDATIONS

- Castration is recommended. Abdominal surgery would be necessary to perform castration.

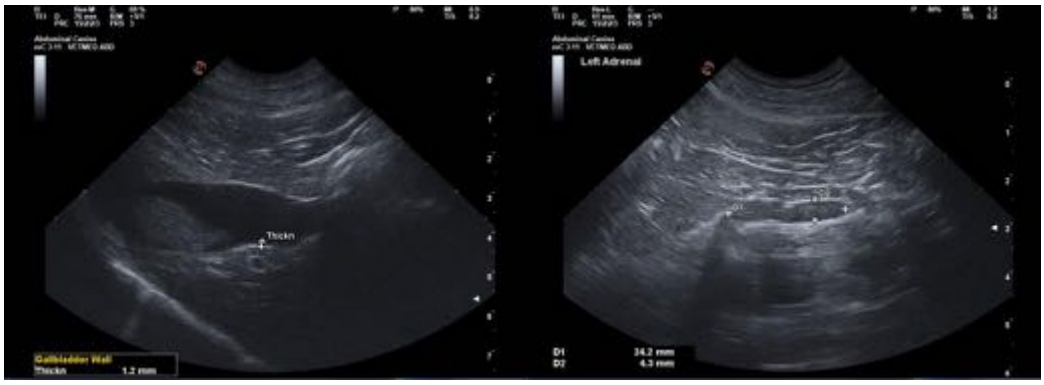

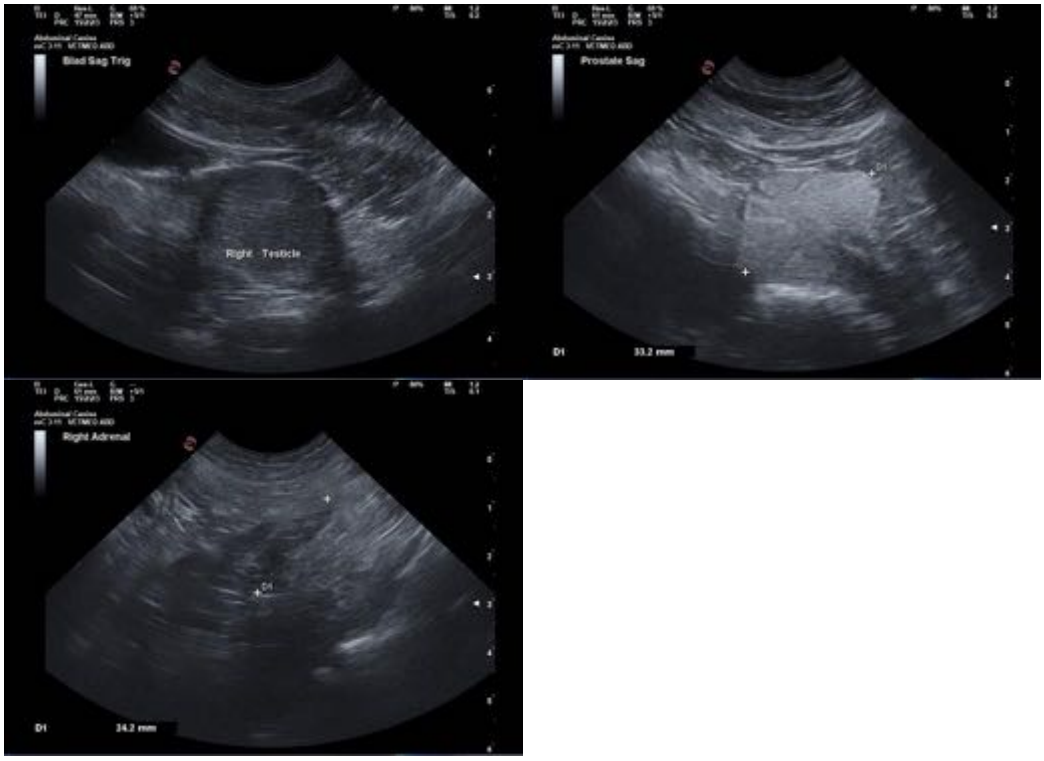

The information and recommendations provided are based on the images presented by the referring veterinarian/sonographer. No evaluation can be communicated regarding pathology that was not visible in the image/video clips provided.

Thank you for this referral. If the clinical or image interpretation does not parallel your findings or if I can be of any further assistance, please contact me.

Andrea Nicastro, MPH, DVM, Diplomate DACVIM (Small Animal Internal Medicine)
info@SonoPath.com